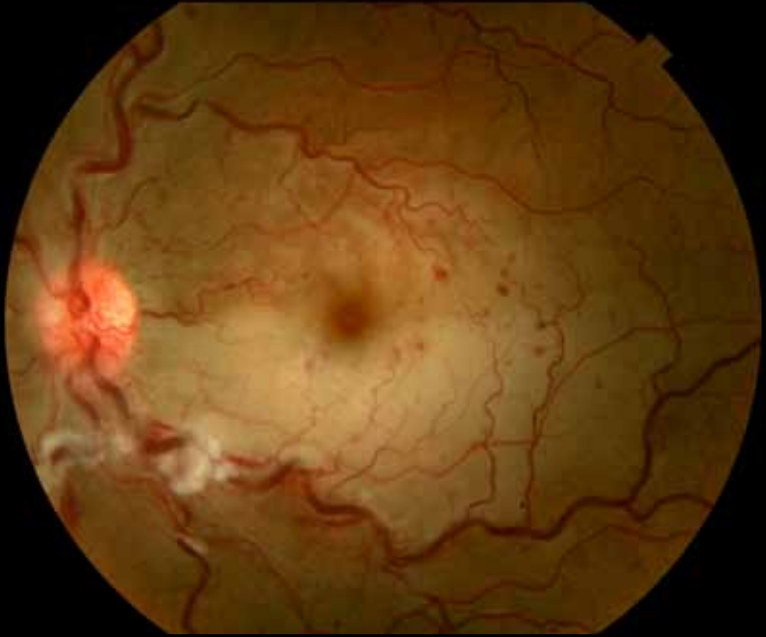


the

LIGHT PIPE

Spring 2012



IN THIS ISSUE:

EMR

Are We Happy
(More Efficient) Now?

pg. 2

Diagnostic Challenge pg. 4-7

What is EYLEA? pg. 7

The Foresee Home Study pg. 8-9

Working to Stomp Out Blindness pg. 10

*The Role of Anticoagulants
and Vitreoretinal Surgery* pg. 11

THE NEWSLETTER OF



GEORGIA RETINA

EMR: Are We Happy (More Efficient) Now?

BY PAUL LUCAS – ADMINISTRATOR/CFO

Almost every practice manager I have spoken with over the last year reports involvement with some stage (research, implementation, training, etc.) of an EMR (Electronic Medical Records) conversion. Motives for such exasperating behavior are widespread—ranging from avoiding pending Medicare penalties to obtaining Medicare incentives to just “the timing was right.”

Whatever the reason, I think we’d all agree it’s not a project for the faint of heart. No matter how thorough the planning efforts for such sweeping change in practice methodology are performed, some unforeseen occurrences are inevitable.

With that in mind, and our EMR conversion effort somewhere between 75%-80% complete, the following tips we learned along the way, are offered in hope of smoothing future transitions:

Initial Planning:

1. Consider an experienced consultant to help work through the many system options, contract negotiation, office infrastructure requirements, implementation planning process, training, implementation, and re-training efforts. While it is an added cost, the scope of the tasks can be overwhelming for a small administrative staff. The consultant keeps the EMR ball rolling, prompting action as needed, while the admin team performs their other full-time job of running the day-to-day practice operation.
2. Select a physician to “champion” the project, preferably one with some “tech savvy”. This go-to doc will be an important liaison for demos, implementation planning, and development of efficient practice pattern changes the practice will be required to make.
3. Less than 110% commitment from all physicians is not an option. Only proceed when all parties are on board, as there is no room for naysayers if the project is to be successful.
4. Don’t put firm timetables on the process. Again, refer to #3 above, allow as much time as is necessary to ensure all physicians buy in to each decision throughout the process.

Implementation:

1. One office at a time! Allow all the kinks to be worked out at one site, shortening the learning curve for all future sites.
2. Control the number of patients you choose to convert to EMR, rather than cut the schedule. Busy practices can’t put patients off, but they can limit how many convert to EMR each day. This allows

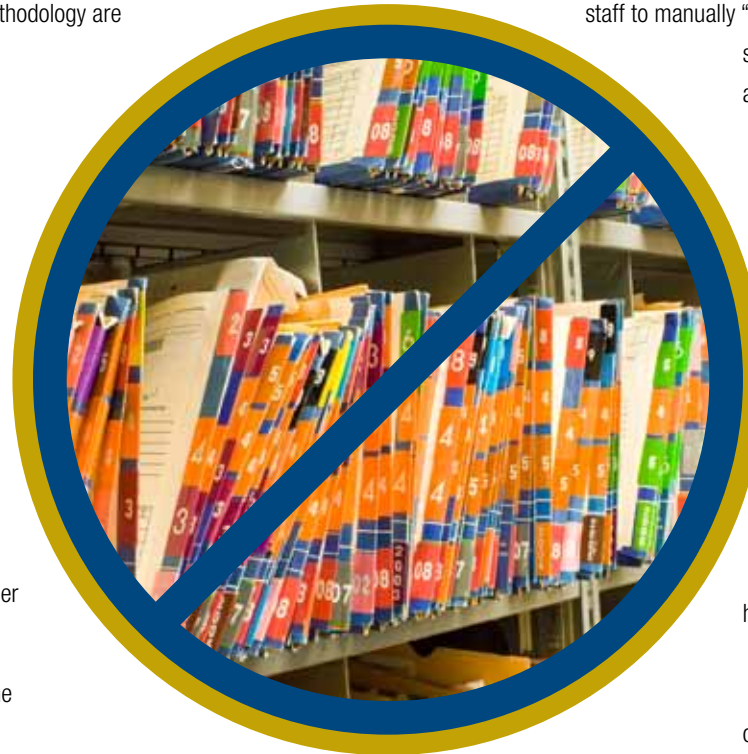confidence with the system to build, resulting in momentum to “ramp up” the EMR volume as the efficiencies are realized by staff and physicians alike. Again, don’t mandate an accelerated pace at which conversion occurs – allow each office/physician to determine it based on their comfort level, thereby keeping the process at a manageable stress level.

3. Conversion from paper to EMR generally requires a patient’s prior history be entered. Require the staff to manually “prep” these EMR charts in advance of the patient’s initial EMR visit. The staff keying in past visit info, surgical history, etc. will reinforce training and identify which personnel may make your best Scribes.

4. If you implement office by office, pick the office in which your EMR physician champion works to start with. The prior efforts to this point will make the full capacity of the system easier understood and build early momentum and hopefully excitement at the other offices soon to go online.

5. Choose your Scribes carefully. Sometimes, the doctor’s long-time assistant will not be the best Scribe, sometimes they will. Obviously only an experienced person should be the initial Scribe; however proficiency with a computer keyboard, mouse and (possibly) multiple monitors is required. The “chart prepping” process in Item 3 above will help identify the strongest candidates.

6. Don’t start the second location until you feel you’ve worked all or most of the operational kinks out with the first location.

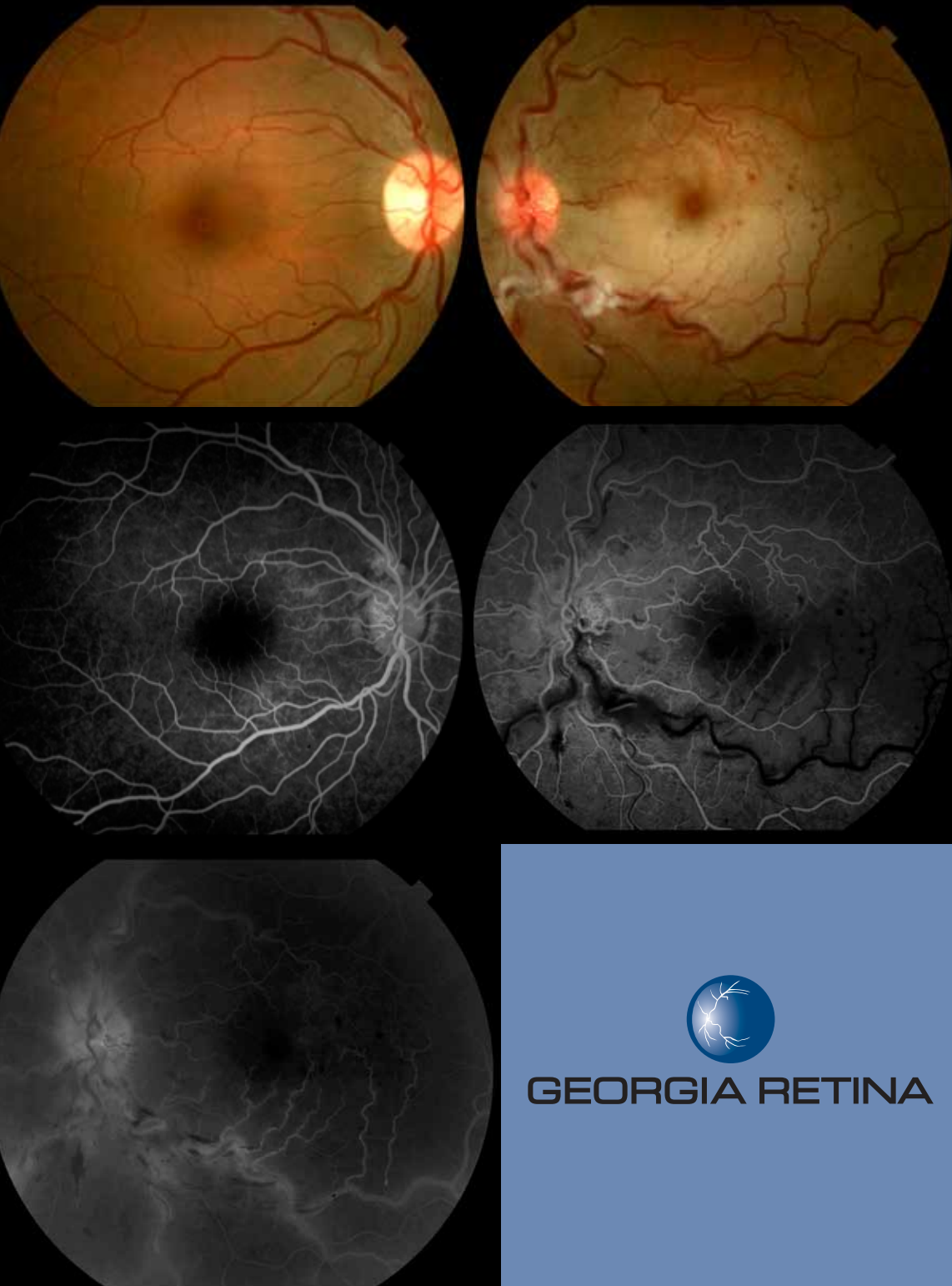

Exam Room Set-up:

1. Dual monitors everywhere (exam room, check in/out) patients are communicated with. Doctors can refer to images, etc. while the Scribe is entering pertinent information.
2. Install a hallway monitor on the wall as a catchall for any staff to review and the doc to open any chart he/she might want to look at *before* going into the exam room.
3. Install a separate high-speed internet connection for the EMR system from that of the phone and other online requirements of the office. Processing speed will be imperative for an efficient experience.
4. As your EMR volume increases, reassess staffing patterns to ensure all functions can be efficiently performed.

I hope these tips are helpful and if you have any questions, please feel free to talk with any of us.

Diagnostic Challenge



BD is a 36-year-old black female who presented to the Northside hospital emergency department with a four-day history of severe decreased central vision in her left eye.

Other than a vague headache on the day of onset, the patient denied all other symptoms and stated her right eye was fine. Her past medical history was remarkable for hypertension for four years, but she was admittedly noncompliant with her medications and her blood pressure was 180/102 on exam for which she was treated with medication. She denied diabetes mellitus (DM) but there was a positive family history of DM. She had arthralgias of her right toes. She had no neurological symptoms and denied STD's. Systemic medications included Prozac and Yaz, an estrogen-based hormone replacement therapy that she recently started for ovarian-related issues.

Visual acuities were 20/20 OD and Count Fingers at two feet OS. The left eye had an obvious afferent papillary defect. Intraocular pressures were normal in both eyes. Her confrontation visual fields were remarkable for a central scotoma in the left eye only.

An in-depth retinal examination with color fundus photographs and fluorescein angiography was performed (see previous page).

What's Your Diagnosis?

An exhaustive workup was undertaken to search for those systemic conditions that could increase her risk of thromboembolism, autoimmune disease, or vasculitis. Given that there were no cells in the anterior vitreous, this lessened the likelihood of retinitis or retinal vasculitis. Results from carotid Doppler studies, ESR, CRP, CBC, PT/PTT, circulating lupus anticoagulant, ANA, serum viscosity, SPEP, Factor V Leiden, antithrombin III, protein C and S deficiency, cryoglobulins, homocysteine, hemoglobin A1c, Factor II mutation, and sickle prep were all negative. Besides an incidental finding of trace aortic regurgitation, the echocardiogram was negative.



GEORGIA RETINA

Diagnostic Challenge

Diagnosis

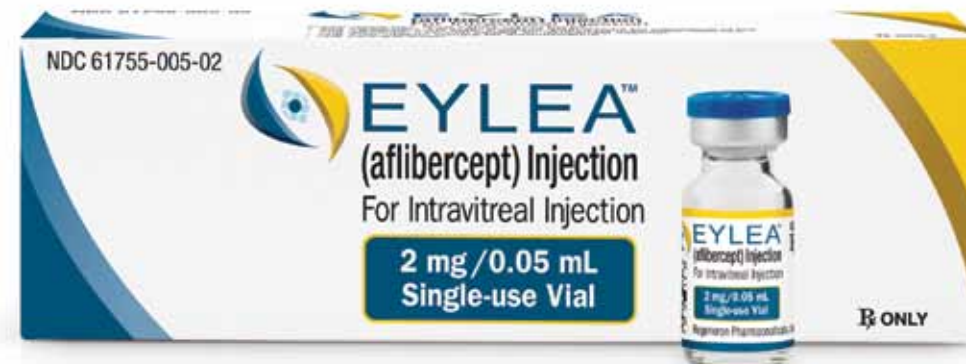Diagnosis:

1. Early impending retinal vascular occlusion, OD. There was definitive edema at the AV crossing above the disc (This is accentuated by the FA.)
2. Branch retinal artery occlusion with impending CRAO, OS (more clearly demonstrated in the color photograph by the retinal whitening in the inferior macula).
3. Retinal vasculitis/phlebitis, OS (Demonstrated in the late frame of the angiogram).
4. Superimposed hypertensive retinopathy, OU.

Comments:

This is an interesting case. The finding in the asymptomatic right eye was ominous, but also a clue that a systemic problem was likely in play which therefore obligated the extensive workup. If the ESR or CRP were positive, a more extensive inflammatory workup would have been performed, but fortunately they were unremarkable. Obviously, most young hypertensive patients do not develop artery occlusions so the combination of an estrogen hormone replacement therapy and poorly controlled hypertension created the right environment to allow thromboembolism. She was advised immediately to suspend use of all estrogen therapies, started on aspirin, (but no stronger anticoagulants) and her BP was normalized. She was monitored carefully for advancement in her OD; the edema subsided. She was examined undilated monthly for rubeosis and none developed. She was given monocular precautions. Her VA in the right eye remained well preserved and the vision in the left eye improved only marginally to 20/400.

What is EYLEA?



EYLEA (aflibercept) is the newest FDA approved anti-VEGF medication for the treatment of neovascular Age-related Macular Degeneration. It was approved by the FDA in November 2011 only for use in wet AMD, although additional indications may be added to its approval in the future. Aflibercept is administered by intravitreal injection and may be dosed as frequently as every four weeks, but is statistically equivalent to monthly ranibizumab when given monthly for three doses and then every 8 weeks. This means that patients receiving aflibercept may potentially require fewer injections to control their disease than those on alternate types of anti-VEGF therapy.


The aflibercept molecule is a fusion protein consisting of fragments of the VEGFR-1 and VEGFR-2 receptors (those receptors responsible for binding all subtypes of VEGF-A and also PlGF (placental growth factor)). The binding of VEGF to the aflibercept molecule is much stronger than the binding to native receptors. The additional blockade of PlGF may also enhance the efficacy of the drug, since other available anti-VEGF medications do not block this molecule.

The efficacy and safety of aflibercept were assessed in the View 1 and View 2 trials (VEGF Trap: Investigation of Efficacy and Safety in Wet AMD). These are multi-center, active controlled, double masked trials in the United States and Europe with a combined total of 2,457 patients with wet AMD. More than 90% of the patients completed the trial through week 52. Patients were assigned to one of four treatment groups. These trials were designed as non-inferiority trials to compare aflibercept to the currently available gold standard medication (ranibizumab).

The primary endpoint of the View trials was the proportion of patients with the prevention of moderate vision loss, defined as losing fewer than 15 ETDRS letters at week 52 compared to baseline. The secondary endpoints were the mean change in visual acuity and the proportion of patients who gained at least 15 ETDRS letters of vision. Patients randomized to the group receiving injections every 8 weeks (after 3 initial monthly injections) received 7.6 injections in the first year of the trial, whereas those in the other three groups received an average of 12.2 injections in the first 52 weeks. Over the last 40 weeks of the study, those in the q8 week arm had five scheduled injections versus 10 scheduled injections in the other three arms of the trial.

continued on page 9

The Foresee Home Study

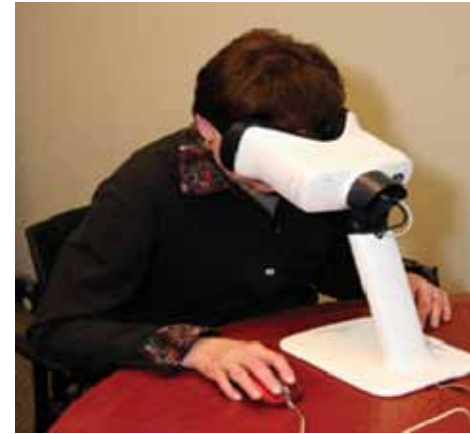

Georgia Retina is a study center for the Foresee Home study, a clinical trial of a new device for home self monitoring by patients with age-related macular degeneration. As we have all experienced, some patients have difficulty using the Amsler grid and are unable to recognize new metamorphopsia. Sometimes this is due to pre-existing baseline visual distortion and relative scotomas associated with atrophy.

The device is known as a preferential hyperacuity test. It was designed in Israel, and is manufactured by Notal Vision. The device presents patients with a line of LEDs which have a bump. Using a computer mouse, the patient clicks on the hump in the line. No actual computer is necessary. The device is connected to a data monitoring center through a standard telephone line. No internet connection is necessary. In the study, patients are being randomized to either test their vision in the standard way, using an Amsler grid, or to have the device placed in their home. They are asked to do their assigned test daily.

Patients are eligible to participate if they are over 50 and have bilateral large drusen or if they have large drusen in one eye, after having developed advanced AMD in the other eye. The study is still enrolling, and it still unknown whether there is any advantage of the device over the standard paper Amsler grid. The hope is that it will result in earlier detection of the conversion from dry AMD to wet AMD, so that appropriate treatment may be promptly instituted. Early detection and treatment generally results in better visual outcomes.

While the device is approved already by the FDA, there is currently no reimbursement available for it through either Medicare or private insurers. Of course, within the context of the study, there is no cost to the patients.



This study began as an extension of the AREDS study, a National Eye Institute sponsored clinical trial of vitamin supplementation for AMD. As a site for the AREDS study, Georgia Retina was an early participant in this trial. We have currently enrolled nine AREDS2 patients and 24 patients outside the AREDS2 study and are pleased to be able to offer this.

continued from page 7

What is EYLEA?

In terms of the efficacy, both the 2mg every four weeks and the 2mg every eight weeks dosing arms of aflibercept were statistically equivalent (non-inferior) to the ranibizumab arm. The results of all arms of the trial were similar in terms of both the mean change in visual acuity and the mean change in retinal thickness. About 30% of patients in all four arms of the study gained at least 15 ETDRS letters of visual acuity. Specifically, 32.4% of the monthly ranibizumab patients and 31% of the bimonthly aflibercept patients gained at least 15 letters. Approximately 20% of patients lost acuity during the trial with no statistical difference among all four arms of the study. A breakdown of the serious ocular adverse events, systemic hypertension, and arterial thromboembolic events was also similar at 1.8% in the combined aflibercept groups. In short, the safety of aflibercept appears to be similar to that of ranibizumab.

In summary, aflibercept dosed on alternate months appears to be similar in efficacy to ranibizumab monthly dosing. In actual practice, however, ranibizumab is often used on a less-than-monthly basis. Additional studies will be required to evaluate whether or not the use of bimonthly aflibercept actually results in the administration of statistically significantly fewer intravitreal injections for patients on this therapy when compared to those receiving other anti-VEGF medications including ranibizumab and bevacizumab (Avastin). Over a two-year period, aflibercept patients received on average 11.2 injections compared to 16.5 ranibizumab injections, but this difference was lower in year two of the study at 4.2 and 4.7 injections respectively. Still, this new medication may represent an effective alternative medication for patients who do not fully respond to other anti-VEGF medications. Finally, monthly dosing of aflibercept may prove to be statistically superior to ranibizumab in future studies.

Additional studies are currently underway to investigate the use of aflibercept for retinal vein occlusion (COPERNICUS and GALILEO trials) and diabetic macular edema (DA VINCI, VIVID, and VISTA trials).

Working to Stomp Out Blindness!

Georgia Retina participated in the 6th annual Atlanta *VisionWalk* hosted by the Foundation Fighting Blindness as a community sponsor. The 3K walkathon was located at Piedmont Park on Sunday, March 25th. *VisionWalk* was organized to increase awareness and raise money for preventions, treatments and cures for blindness. With a walking team of 81, Georgia Retina was the largest participating group in the state of Georgia and raised over \$2,500 for the Foundation Fighting Blindness!

Foundation Fighting Blindness was established in 1971 by a group who wanted more time and research to combat vision-robbing retinal degenerative diseases. These diseases, which include macular degeneration, retinitis pigmentosa and Usher syndrome, affect more than 10 million Americans and millions worldwide. Today, the Foundation Fighting Blindness is a thriving national nonprofit group which supplies the leading source of funding for retinal disease research.

Georgia Retina hopes that giving our support to the *VisionWalk* and contributing to the foundation help our patients and others worldwide.



The Role of Anticoagulants and Vitreoretinal Surgery

As vitreoretinal surgeons, we strive to provide our patients with the best possible outcomes both in the office and in the operating room. In several of our patients, the discussion and decision to stop anticoagulants before elective and emergency surgery poses a significant dilemma for the ophthalmic surgeon. Anticoagulants such as coumadin (Warfarin), Plavix, and Aspirin are generally used for the management of potentially life-threatening conditions such as atrial fibrillation, other cardiac arrhythmias, preventing pulmonary emboli, cardiac valve surgery, and in patients who have undergone coronary artery bypass grafts.

The withdrawal of anticoagulants prior to surgery (especially for elective surgery) increases the risk to the patient for developing a myocardial infarction, pulmonary embolus, deep venous thrombosis, and strokes. There is evidence now in the retinal literature suggesting that these patients may safely undergo vitreoretinal surgery while maintaining therapeutic levels of anticoagulation (coumadin), defined as an International Normalized Ratio (INR) from 2.0 to 2.49. Coumadin has a biologic half life of 36-42 hours and, after cessation, requires several days for the INR to “normalize.” We usually tell patients to stop using coumadin four days prior to surgery (after getting clearance from their cardiologist) in order to ensure that their INR falls to a normal level. It also takes a few days to get back to therapeutic levels, once coumadin is restarted. Therefore, there are potentially several days in-between the cessation and the restarting of coumadin where the patients’ INR is normalized. This period is when potential complications can occur.

Dayani *et al* performed a retrospective review of 57 vitreoretinal surgeries on patients who were still on coumadin and found that no patients suffered anesthesia related or intraoperative hemorrhagic complications. Postoperative hemorrhage was noted in some of these patients which spontaneously cleared without additional therapy. The anesthesia utilized was local infiltrative anesthesia which consists of topical anesthesia, followed by the creation of sunconjunctival bleb. After performing a small limbal incision to allow for dissection of Tenon’s capsule, a blunt-tipped curved cannula can then be passed through to the retrobulbar space in order to provide additional anesthesia and akinesia needed for vitreoretinal surgery. This method of anesthesia avoids the potential complications of a standard retrobulbar injection, namely a retrobulbar hemorrhage.

We are excited that there is growing evidence that supports maintaining our patients on anticoagulating agents prior to vitreoretinal surgery. There are several patients with diabetic-related hemorrhages, macular puckers and holes that have been prevented from having elective procedures performed due to their anticoagulation needs. These patients can now significantly improve their quality of life without the need for anticoagulant cessation prior to surgery.

Reference: Dayani PN, Grand G. Maintenance of Warfarin Anticoagulation for Patients Undergoing Vitreoretinal Surgery. *Trans Am Ophthalmol Soc.* 2006. 104: 149-160

Participating Insurance Plans:

Aetna U.S. Healthcare
BCBS of Georgia
Beech Street
Blue Choice
CCN PPO
Choice Care Network
Cigna
Coventry Healthcare
Evolutions Healthcare System
First Health
Great-West
Humana
Medicaid
- Peach State Medicaid
- Wellcare Medicaid
- Amerigroup Medicaid

Medical Resource Network
Medicare
Medicare Railroad
Multiplan PPO
National Preferred Provider
Network
Novanet
Private HealthCare Systems
Southcare PPO
TriCare PPO, HMO
State Health
United Healthcare
USA Managed Care Organization
WellCare Medicare HMO

Other plans are pending; please call to check specific participation.

(770) 907-9400

Disclaimer: No contract, representations or promises are made, given or intended by any materials, information, and/or suggestions contained in this newsletter. The authors and publisher make no representations or warranties with respect to any treatment or action relied upon or followed by any person receiving information presented without warranty of any kind. In addition, neither our Practice nor any individual associated or affiliated with our Practice endorses or recommends any specific medical service, clinical study, medical treatment or commercial product. All text, copy, graphics, design, and other works are the copyrighted works of Georgia Retina, P.C. All rights reserved. Any redistribution or reproduction of any materials herein is strictly prohibited.

Our Physicians: Michael S. Jacobson, M.D. | Scott Lampert, M.D. | Mark J. Rivellese, M.D.
Jay B. Stallman, M.D. | Sean S. Koh, M.D. | Atul Sharma, M.D. | Robert A. Stoltz, M.D. | John J. Miller, M.D.
Stephanie L. Vanderveidt, M.D.

465 Winn Way, Ste. 100
Decatur, GA 30030
(404) 299-5209

1100 Johnson Ferry Rd.
Bldg. 2, Ste. 593
Sandy Springs, GA 30342
(404) 255-9096

833 Campbell Hill St., Ste. 300
Marietta, GA 30060
(770) 218-1888

575 Professional Dr., Ste. 330
Lawrenceville, GA 30045
(678) 405-0922

6065 Professional Pkwy.,
Ste. B202
Douglasville, GA 30134
(678) 303-0136

960 Sanders Road, Ste. 500
Cumming, GA 30041
(678) 679-4830

403 Westpark Ct., Ste. 110
Peachtree City, GA 30269
(770) 486-5349



GEORGIA RETINA

PRSRT STD
US POSTAGE PD
CUMMING, GA
PERMIT 107